

To investigate the safety, efficacy, and stability of Trans Epithelial PRK performed with LaserSoft **solid-state** 210 nm photorefractive laser platform after 9 months follow up.

PURPOSE

NO FINANCIAL INTEREST

Dr Ashish Nagpal

MBBS, DNB, DO, FRCS

Wavelase Eye Centre and
Centre for Cornea

Ahmedabad, INDIA

drashishnagpal@gmail.com





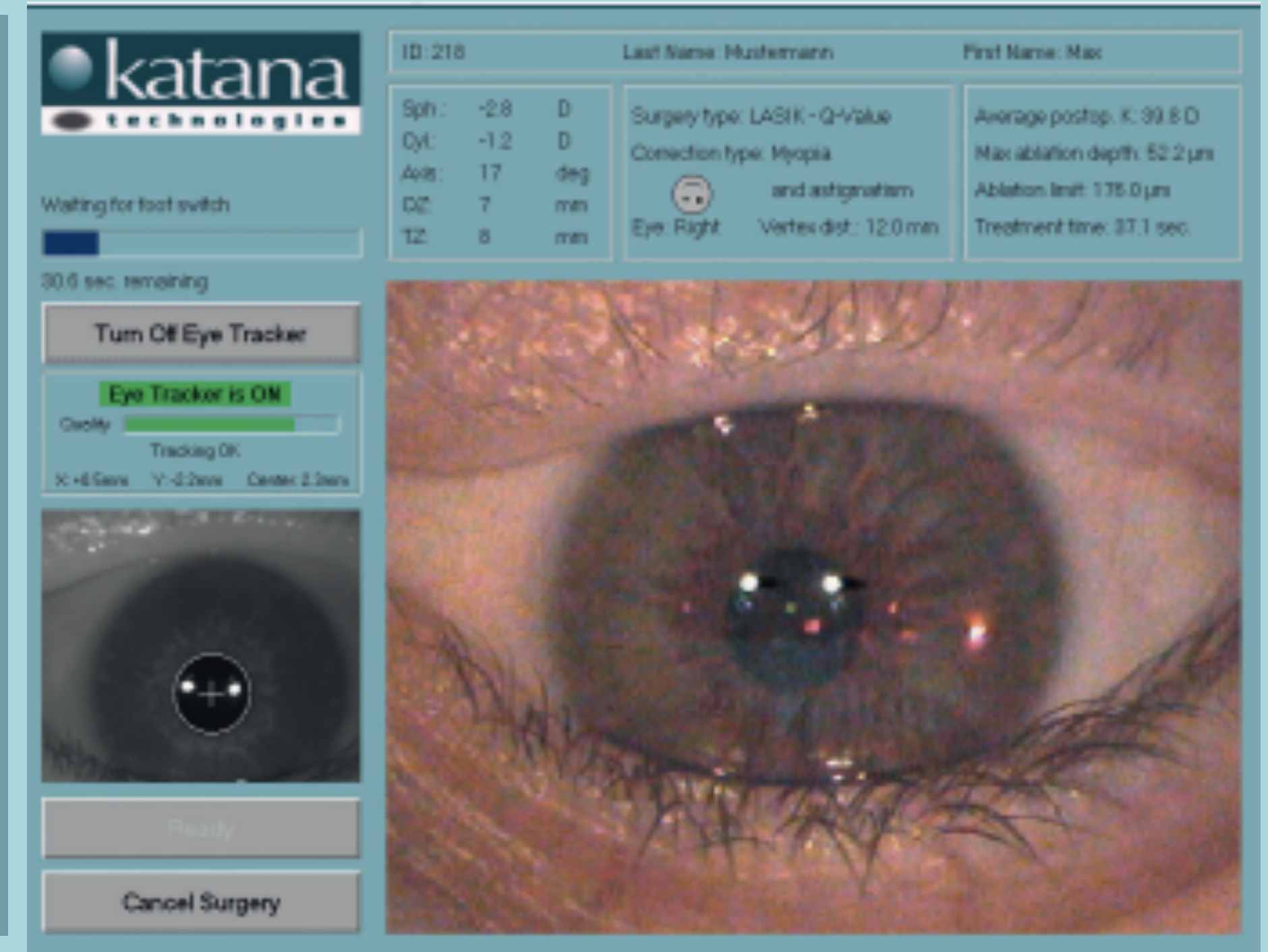
METHODS

Transepithelial PRK was performed with the small spot size, high-repetition rate, all-solid-state LaserSoft (Katana Technologies, Berlin, Germany), which is a stabilized, tunable short-pulse, Q-switched, frequency-shifted, and diode-pumped laser.

Wavelength : 200 and 210 nm.

Repetition rate : 2 kHz.

Eye Tracker : The laser's eye tracker system has a latency of 1 millisecond.



19 eyes of ten patients underwent Transepithelial PRK

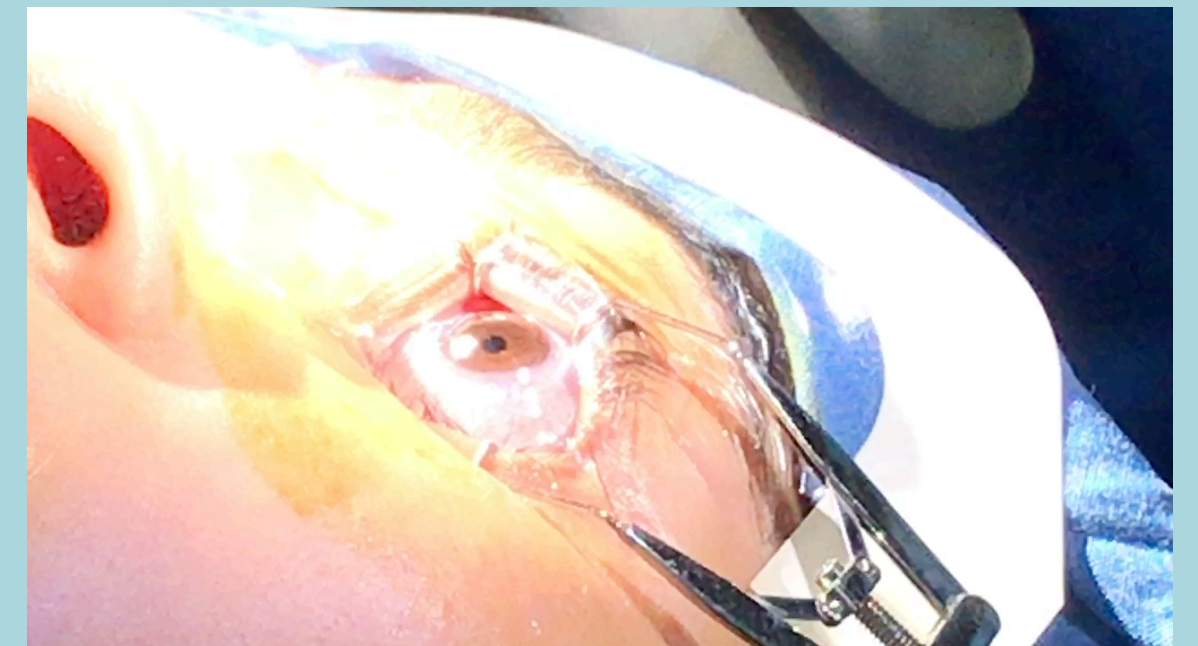
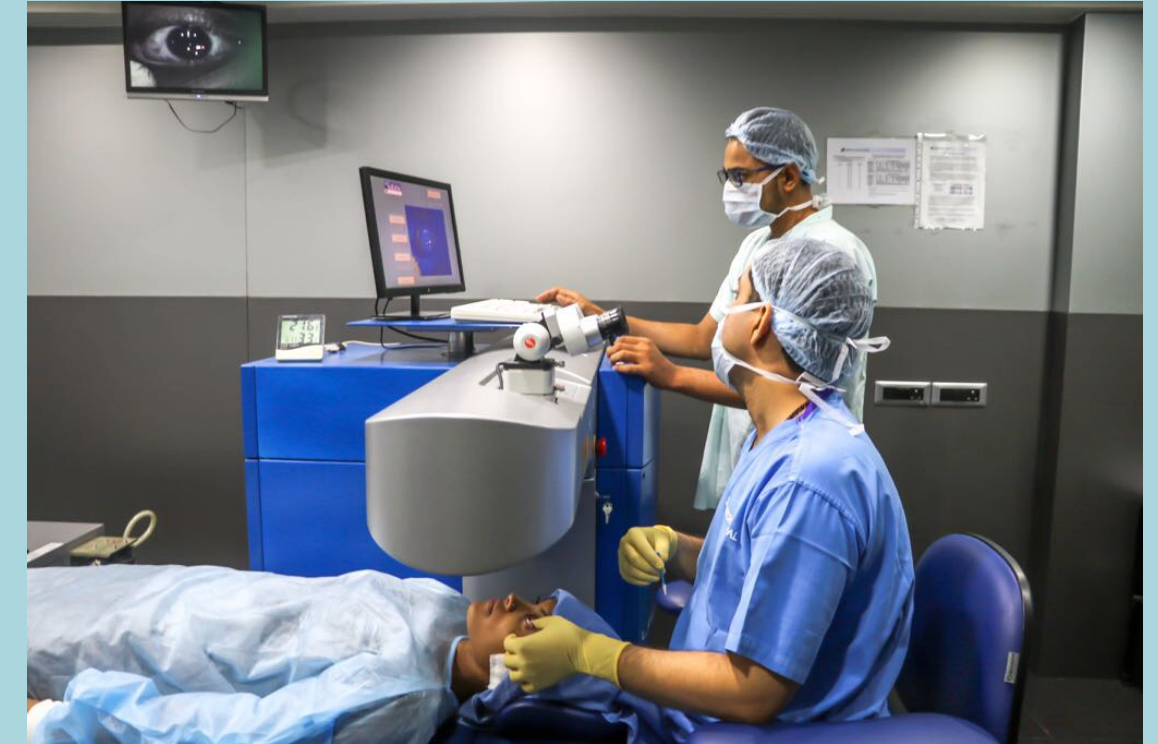- Preoperative assessment included uncorrected visual acuity (UCVA), best spectacle-corrected visual acuity (BSCVA), tonometry, corneal tomography, cycloplegia refraction, ophthalmoscopy, pupillometry and endothelial microscopy.





METHODS

- Patients were excluded if they had change in refraction within the past year, corneal pathology, glaucoma, or systemic diseases (eg, diabetes and immunologic disorders).
- Informed consent was obtained from all patients.
- One surgeon (APN) performed **Transepithelial PRK** with MMC with LaserSoft (Katana Technologies, Berlin, Germany)
- **Spot diameter** was 0.2 mm
- **PTK ablation zone** varied up to 9 mm. PTK depth was 52 microns for all patients.
- **PRK ablation zone** varied upto 8mm .
- Mitomycin C (0.02%) was applied for 30 seconds in all eyes.
- Bandage Contact Lens was placed for 3 days till the epithelium healed.
- All patients received drops of antibiotics, steroids, and artificial tears 4 times daily till the bandage Contact lens was removed.
- Corticosteroid drops were continued till 2 months and Artificial Tears till 3 months.
- The examinations were performed at 1, 3, 6, and 9 months postoperatively





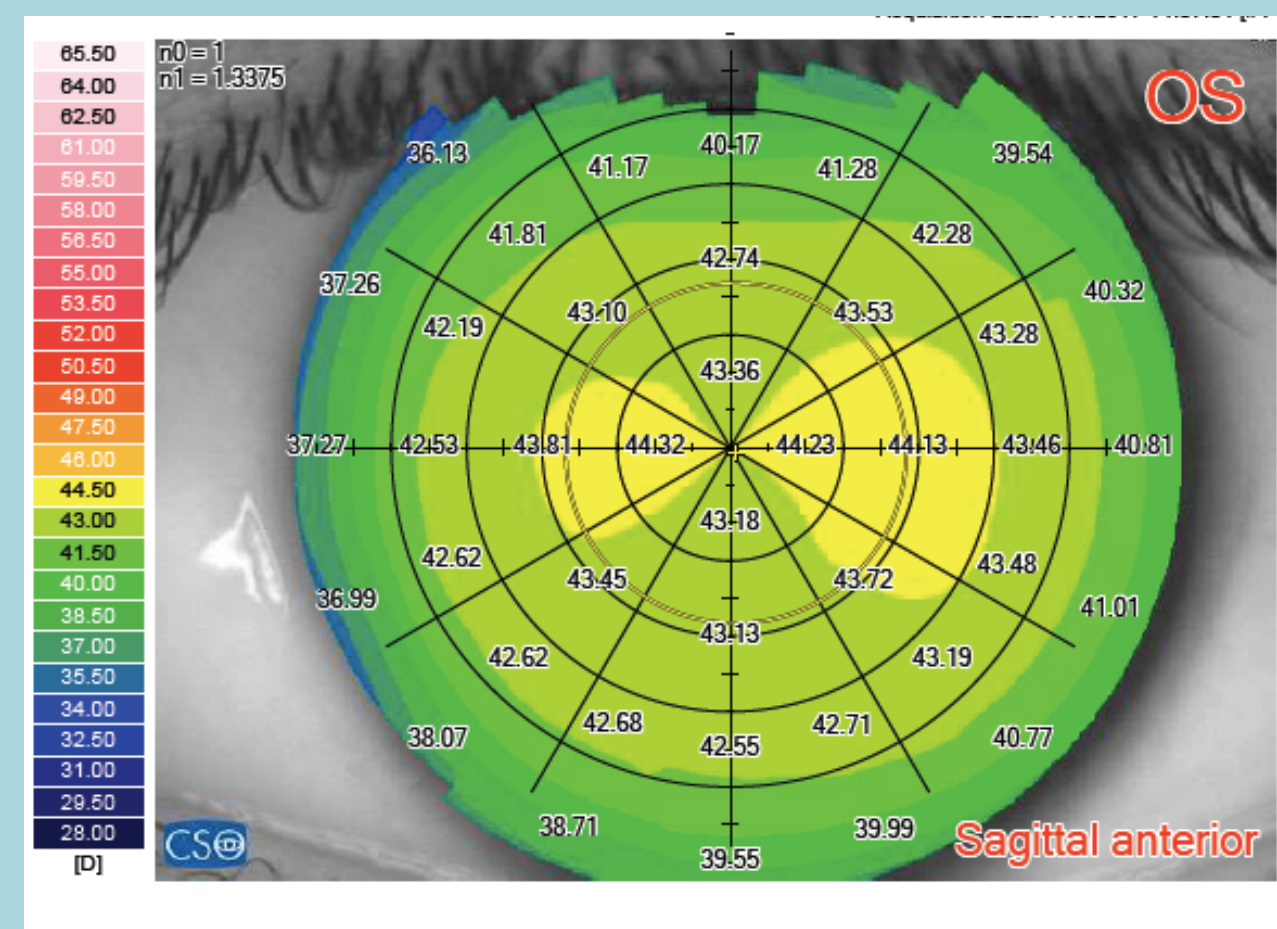
VISUAL ACUITY

At 9 month follow up no eye lost lines of BSCVA and UCVA improved in all eyes. All eyes were within 1.00 diopters (D) and 15 eyes were within 0.50 D of emmetropia

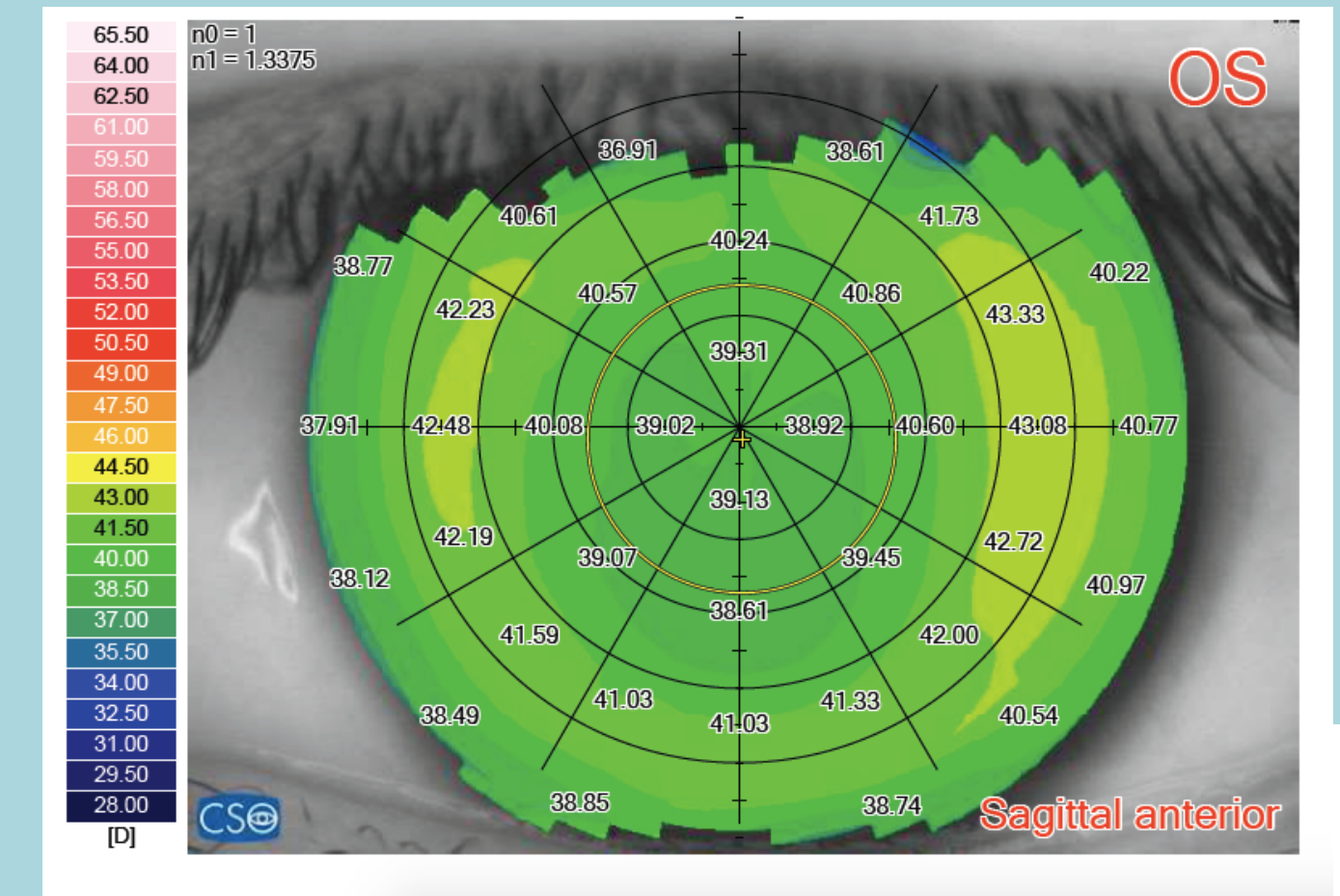
CORNEAL TOPOGRAPHY

Corneal maps demonstrated a smooth regular pattern and well centered ablation zones

OBSERVATIONS



BEFORE



AFTER





CORNEAL TRANSPARENCY

All eyes had clear transparent corneas at 9 month follow up. Both eyes of one patient with refractive error of -6 diopters developed haze which cleared up by 3rd month with topical steroids.

OBSERVATIONS

CORNEAL ENDOTHELIAL SPECULAR MICROSCOPY

Specular Microscopy was possible in 15 eyes and the post operative counts and morphology were similar and comparable to the pre operative .





Clinical results of **Transepithelial PRK** were promising, with **good safety profile**, efficacy and stability of the visual and refractive outcome.

Transepithelial PRK with the Lasersoft truly offers a **painless, touchless procedure to the patient**.

Moreover the **noiseless laser delivery** also ensured a far more comfortable patient experience and better compliance.

A **larger sample size** of patients would offer a better perspective on Transepithelial PRK with the Lasersoft.

SUMMARY

